



The case for adding X-linked agammaglobulinemia to newborn screening

ABSTRACT

X-linked agammaglobulinemia typically presents in infancy or childhood with microbial infections as a consequence of low to absent mature B cells and pan-hypogammaglobulinemia, caused by mutations in BTK. However, atypical presentation in some cases may delay the diagnosis as well as the implementation of appropriate replacement therapy.

X-linked agammaglobulinemia (X-LA) is caused by mutations in the *BTK* gene that encodes Bruton's tyrosine kinase, resulting in the arrest of B-cell development (Bruton 1952; Tsukada et al. 1993; Vetrie et al. 1993). Characteristically, these patients have no visible tonsils, no palpable lymph nodes, no detectable circulating B-cells dysplastic lymph nodes (Figures 1 and 2), and extremely low-to-absent serum levels of immunoglobulins G, M, and A (IgG, IgM, and IgA). As a consequence patients may suffer repeated and sometimes fatal infections with encapsulated bacteria and enteroviruses unless treatment with IgG replacement is administered.

Unfortunately, unless a family history exists, this condition may not be suspected or detected in a timely fashion for several reasons:

1. This a rare condition and is usually not suspected by primary care providers.
2. Symptoms most frequently include upper respiratory infections and otitis media, which are common in the "healthy" pediatric population.
3. Maternal-fetal transfer of IgG provides protection from microbial infections during the first few months of life.
4. X-LA may have an atypical presentation (Hashimoto et al. 1999).

The following case, together with other cases as presented by Nahum et al. on page 75, highlight the need for promoting tools for the early diagnosis of this condition.

A male, 2 years and 4 months of age, born to noncon-sanguineous parents of Polish descent, suffered from repeated upper respiratory tract infection and otitis media from the age of 6 months. Myringotomy tubes inserted at 1.5 years of age reduced morbidity dramatically. On examination he had palpable lymph nodes in the cervical area and his growth and development were appropriate for his age. At 2 years of age he was admitted to hospital for fever, coryza, and cough lasting several days. Upon examination, he was found to have lymphadenopathy in the cervical area. A throat swab was positive for Group A streptococcus and he responded well to antibiotic therapy. Three months later he was examined in an emergency room for a 3-day course of fever, coryza, and vomiting. He was sent home with a possible diagnosis of a viral infection, only to return 24 hours later with persisting fever, red eyes, diarrhea, hypotension, and tachycardia. A CT scan revealed cervical adenopathy on the right and left neck mass abscesses (Figures 3–5). Petechiae were noted on the arms, face, and chest. Immune evaluation revealed normal numbers of circulating CD3⁺ T cells at 2800 cell/μL, of which 2100 were positive for CD4

Available online 11 September 2014

LymphoSign Journal 2:53–55 (2015)
dx.doi.org/10.14785/lpsn-2014-0010

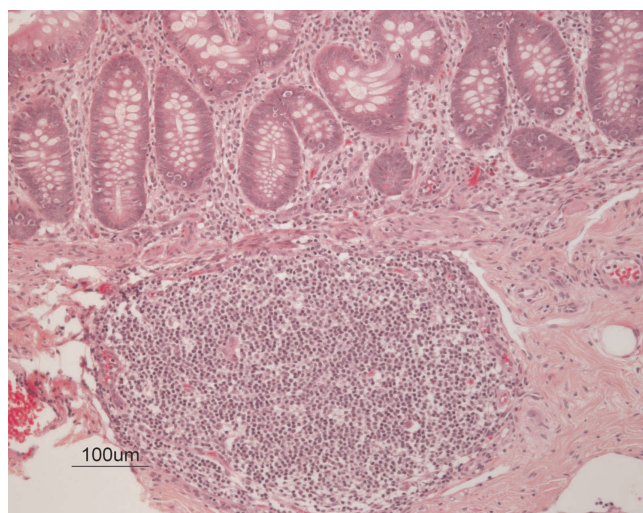


Figure 1: Mucosa-associated lymphoid tissue in the appendix devoid of germinal center development as well as a complete lack of plasma cells in the lamina propria.

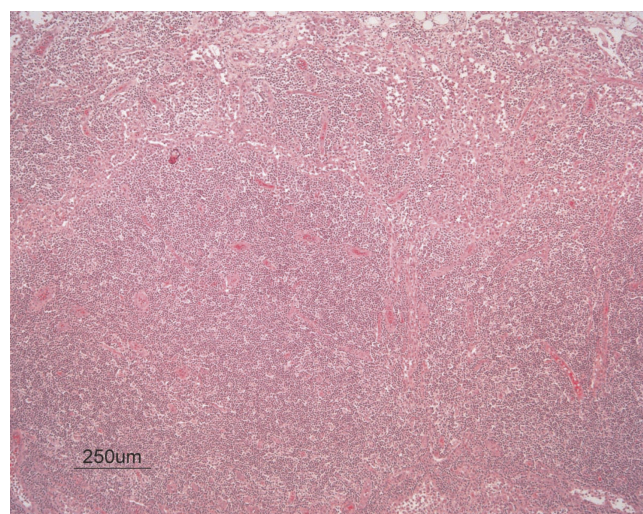


Figure 2: The cortex of the lymph node showed a marked reactive lymphoid hyperplasia with numerous reactive histiocytes and absent germinal center and plasma cells.

and 820 were positive for CD8. CD19⁺ cells were not detected. The patient's IgG, IgM, and IgA were absent. Sanger sequencing showed a C to G transition at position 1275, creating a premature stop codon at amino acid position 425 in the tyrosine kinase domain (Figure 6). He rapidly deteriorated, developing seizures and respiratory failure. He was admitted to ICU with the diagnosis of septic shock and coagulopathy. Blood count showed neutropenia and lymphopenia, and blood cultures were positive for Group A streptococcus. Despite intensive management, the patient's condition rapidly deteriorated and he died of multi-organ failure 9 days after admission.

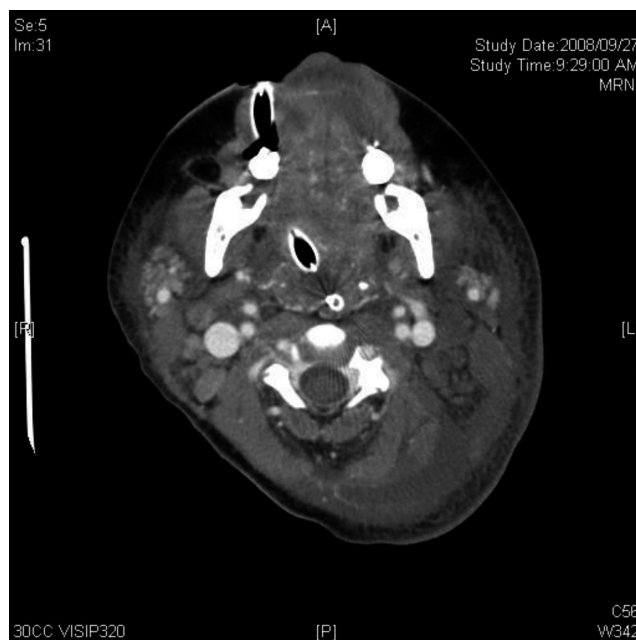

Figure 3: CT scan of the neck shows enlarged cervical lymph nodes on the right and an abscess on the left.

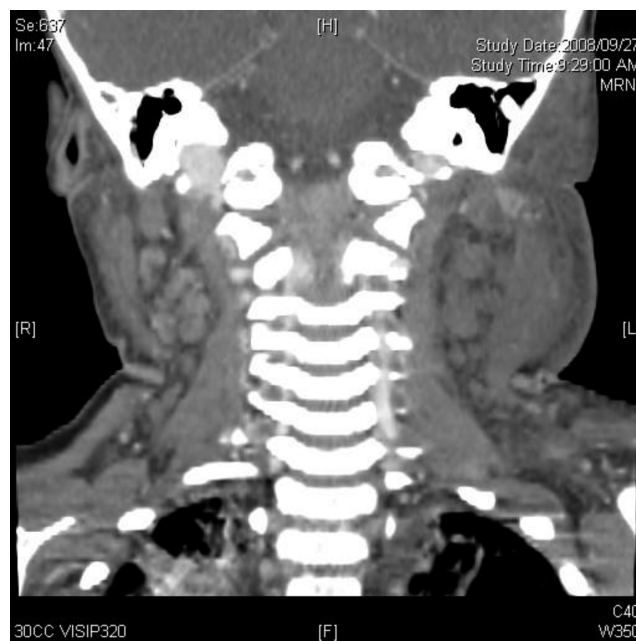

Figure 4: CT scan axial review shows enlarged lymph nodes on the right cervical area.

Autopsy showed lymph nodes in the neck, axillae, and mesentrium. Histology revealed absent germinal centers and very few CD20⁺ B cells but a normal number of CD3⁺ cells. The spleen had no white pulp and B cells were absent. Gut-associated lymphoid tissue was hypoplastic with no germinal centers or B cells.

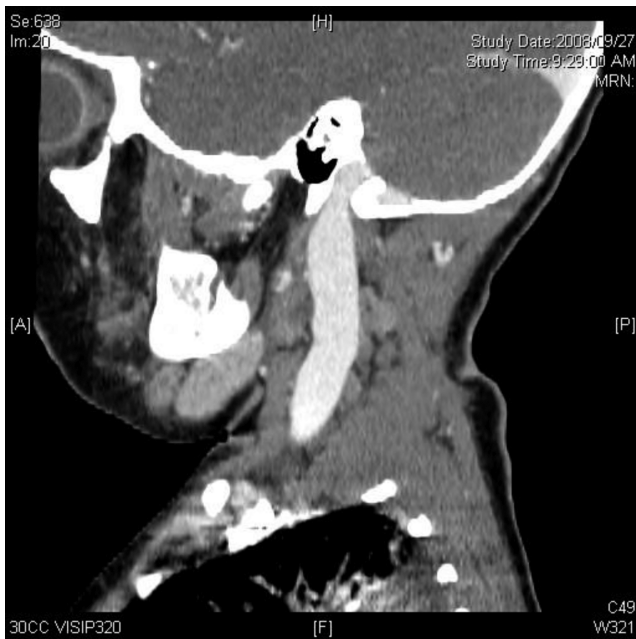

Figure 5: CT scan image shows the presence of tonsillar tissue.

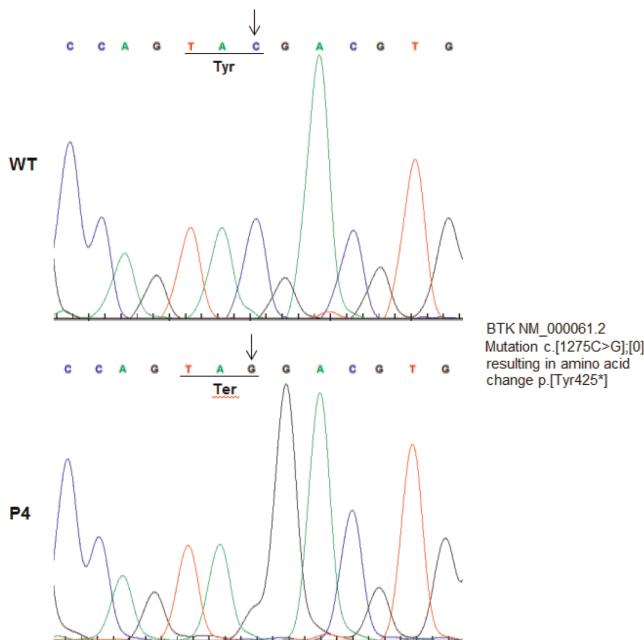


Figure 6: Sequence analysis of the *BTK* gene showing a C to G transition at position 1275.

Kappa-deleting recombination excision circles (KRECs) are circular DNA segments generated in B-cell precursors during maturation in the bone marrow. These DNA elements persist in the cells but

cannot replicate and, therefore, get diluted with every cell division. Their quantification thus, can serve as markers of B cells lymphopoiesis. Recently, the development of reliable real-time quantitative PCR methods has allowed for early screening and detection of conditions that interfere with normal V(D)J recombination such as agammaglobulinemia and several types of severe combined immunodeficiency.

It is alarming that even at this age of modern health care, including intensive care and pharmacologic advancements, X-LA remains a potentially fatal inherited disease. Together with ample evidence for a heavy burden of morbidity in these patients, early diagnosis prior to development of infection is of paramount importance. With the recent development of reproducible methodology for detecting KREC's in Guthrie blood spots, this should be added to newborn screening programs as a lifesaving procedure.

REFERENCES

- Bruton, O.C. 1952. Agammaglobulinemia. *Pediatrics*. **9**: 722–728. PMID: 14929630.
- Hashimoto, S., Miyawaki, T., Futatani, T., Kanegane, H., Usui, K., Nukiwa, T., Namiuchi, S., Matsushita, M., Yamadori, T., Suemura, M., Kishimoto, T., and Tsukada, S. 1999. Atypical X-linked agammaglobulinemia diagnosed in three adults. *Intern. Med.* **38**:722–725. PMID: 10480303. doi: 10.2169/internalmedicine.38.722.
- Tsukada, S., Saffran, D.C., Rawlings, Parolini, O., Allen, R.C., Klisak, I., Sparkes, R.S., Kubagawa, H., Mohandas, T., and Quan, S. 1993. Deficient expression of a B cell cytoplasmic tyrosine kinase in human X-linked agammaglobulinemia. *Cell*. **72**(2):279–280. PMID: 8425221. doi: 10.1016/0092-8674(93)90667-F.
- Vetrie, D., Vorechovski, I., Sideras, Parolini, O., Allen, R.C., Klisak, I., Sparkes, R.S., Kubagawa, H., Mohandas, T., and Quan, S. 1993. The gene involved in X-linked agammaglobulinaemia is a member of the src family of protein-tyrosine kinases. *Nature*. **361**: 226–233. PMID: 8380905. doi: 10.1038/361226a0.

Chaim M. Roifman, MD, FRCP, FCACB
Editor-in-Chief
(croifman@lymphosign.com)